

Intraluminal real-time navigation through long CTOs in the femoral artery

A. Schwindt; J. Schäfers, JJ Desai, G. Torsello

Klinik für Gefäßchirurgie
St. Franziskushospital Münster
Centrum für vaskuläre und endovaskuläre Chirurgie
Universitätsklinik Münster

Arne.Schwindt@SFH-MUENSTER.de

Conflicts of interest:

Honoraria/Consulting/Advisory board/
Proctorship agreement/unrestricted
educational grant

- Avinger
- Biotronik
- Boston Scientific
- Covidien
- Medtronic
- Terumo

Outline

- I. results of established recanalisation methods
- II. introduction Ocelot catheter,
concept of lumिकासculare therapy
- III. Case example
- IV. first results



results of Bolia technique

- In selected patients, percutaneous intentional extra-luminal recanalization (PIER), or subintimal angioplasty, has been advocated as an alternate to surgery for the treatment of long femoropopliteal (FP) occlusions
- Although the technical success rate of PIER is reported at 64-84%, safe and predictable re-entry into the reconstituted true lumen distal to the occlusion remains the limitation of the procedure

Nadal, L.L., et. al., *Techniques in Vascular and Interventional Radiology*, 2004; (7):16-22.



Up to date recanalisation rates with established devices

▪ Crosser CTO Recanalization System (Flowcardia Inc, Sunnyvale, CA now Bard)	70%
▪ TruePath CTO device (Boston Scientific, Natick, MA)	80%
▪ Frontrunner XP (Cordis Corp, Miami, FL)	65% - 90%
▪ Wildcat/Ocelot (Avinger, Redwood City, CA)	90% - 100%
▪ Outback (Cordis Corp, Miami, FL)	86% - 100%
▪ Pioneer (Volcano Corp; Rancho Cordova, CA)	86% - 100%

1. Gandini et al J Endovasc Ther 2009
2. <http://www.bostonscientific.com/truepath/clinical-data.html>? Accessed 2/10/12
3. Charalambous et al. Cardiovasc Intervent Radiol. 2010
4. Mossop et al Catheter Cardiovasc Interv 2006
5. Smith et al Texas Heart Inst J. 2011
6. Jacobs et al J Vasc Surg. 2006;
7. Schwindt Eurointervention 2012 under review



OCELOT – Catheter (Avinger, Redwood City)



TECHNICAL SPECIFICATIONS

Product Catalogue Number:
O100E

Crossing Profile:
2 mm (.080 inches)

Inner Diameter:
.41mm (.016 inches)

Working Length:
110 cm (43.3 inches)

Sheath Compatibility:
6 French

Guidewire Compatibility:
.014 inches

by Courtesy of Avinger INC. Redwood City

OCELOT – Catheter (Avinger, Redwood City)



SPIRAL WEDGES: Corkscrew through CTOs.
OCT IMAGING FIBER: 1.5 mm from distal tip.
PRE SHAPED TIP: Increased directionality.

LOCAL FLUSH: Located right at the imaging fiber.
MANUAL FLUSH: Easily control the amount used.

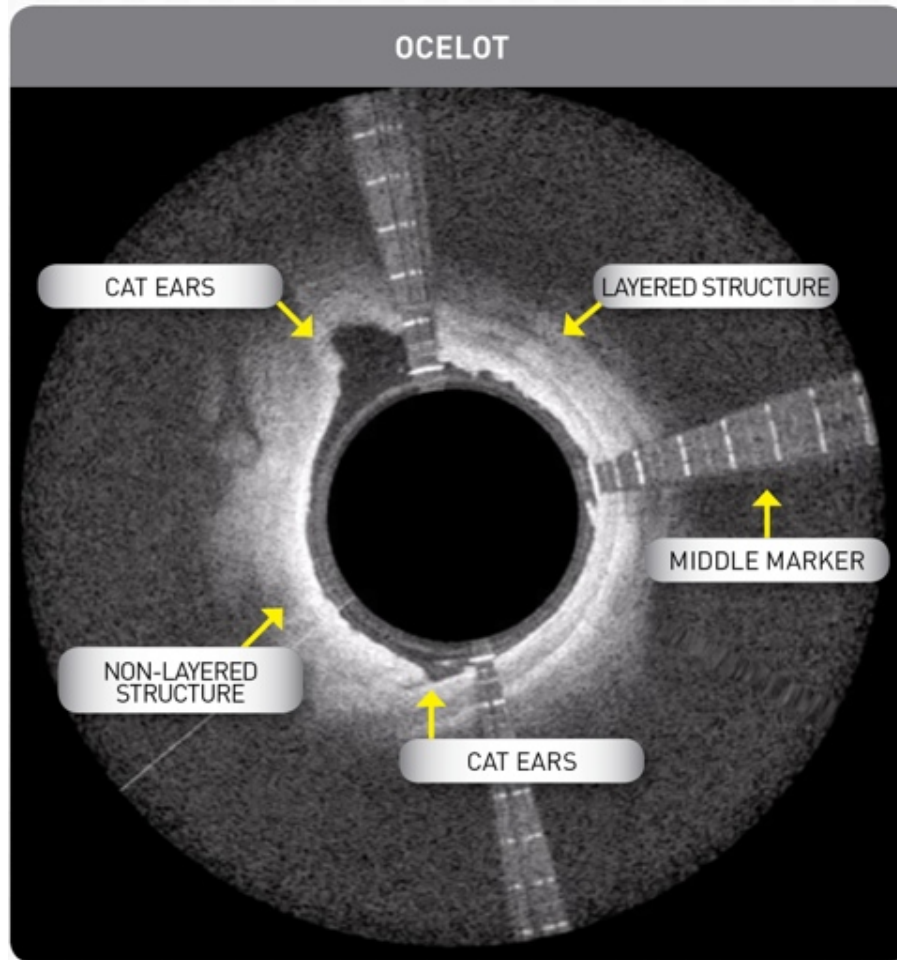


SIMPLE CONTROLS:

- 1) OCT On/Off
- 2) Bi-Directional Torque Knob
- 3) .014 Wire / Flush Lumen



OCT-Imaging in correlation to SFA-morphology

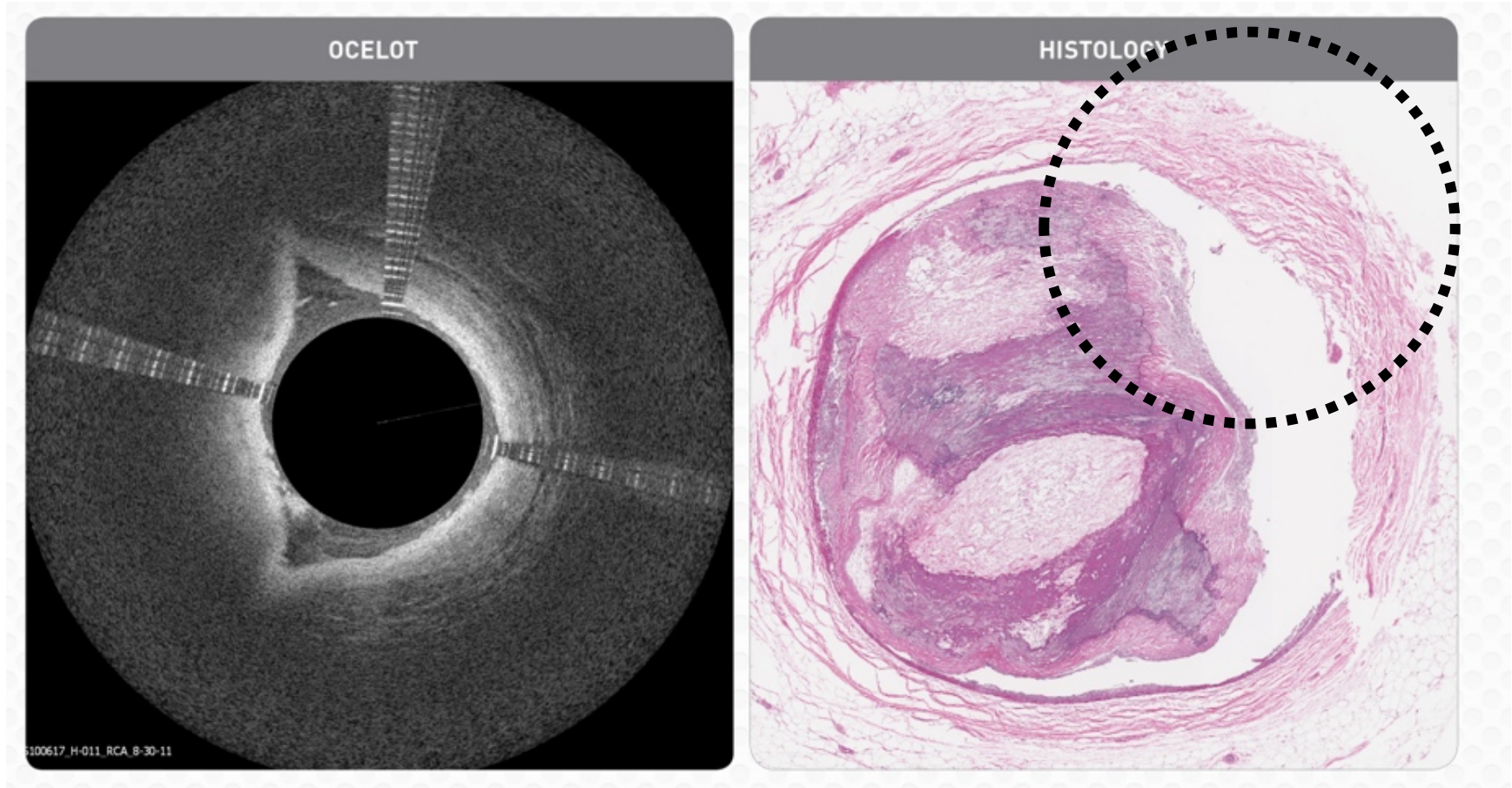


ESTABLISH INTRA-ARTERIAL ORIENTATION.

- ▶ Identify layered vs. non-layered structures.
- ▶ Cats ears to point the way.
- ▶ Orient by middle marker / deflection.



OCT-Imaging in correlation to SFA-morphology

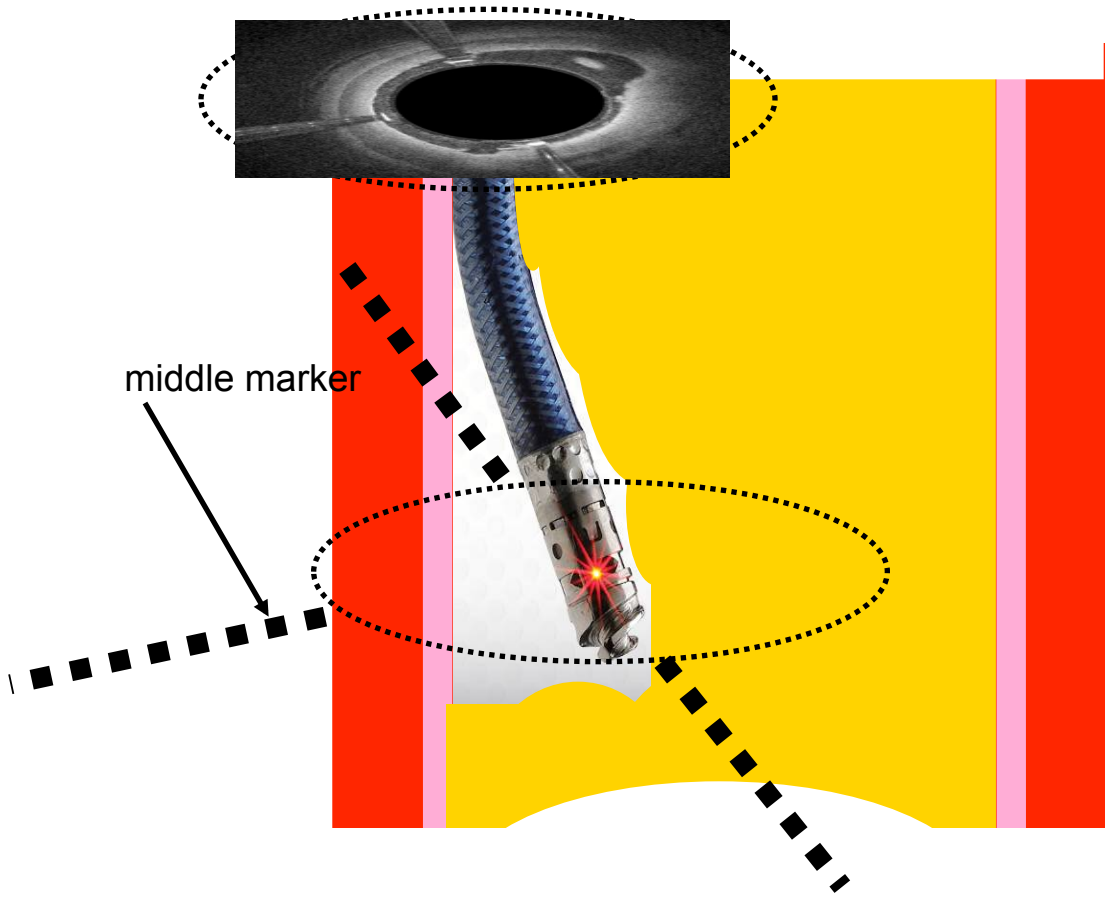


by Courtesy of Avinger INC. Redwood City

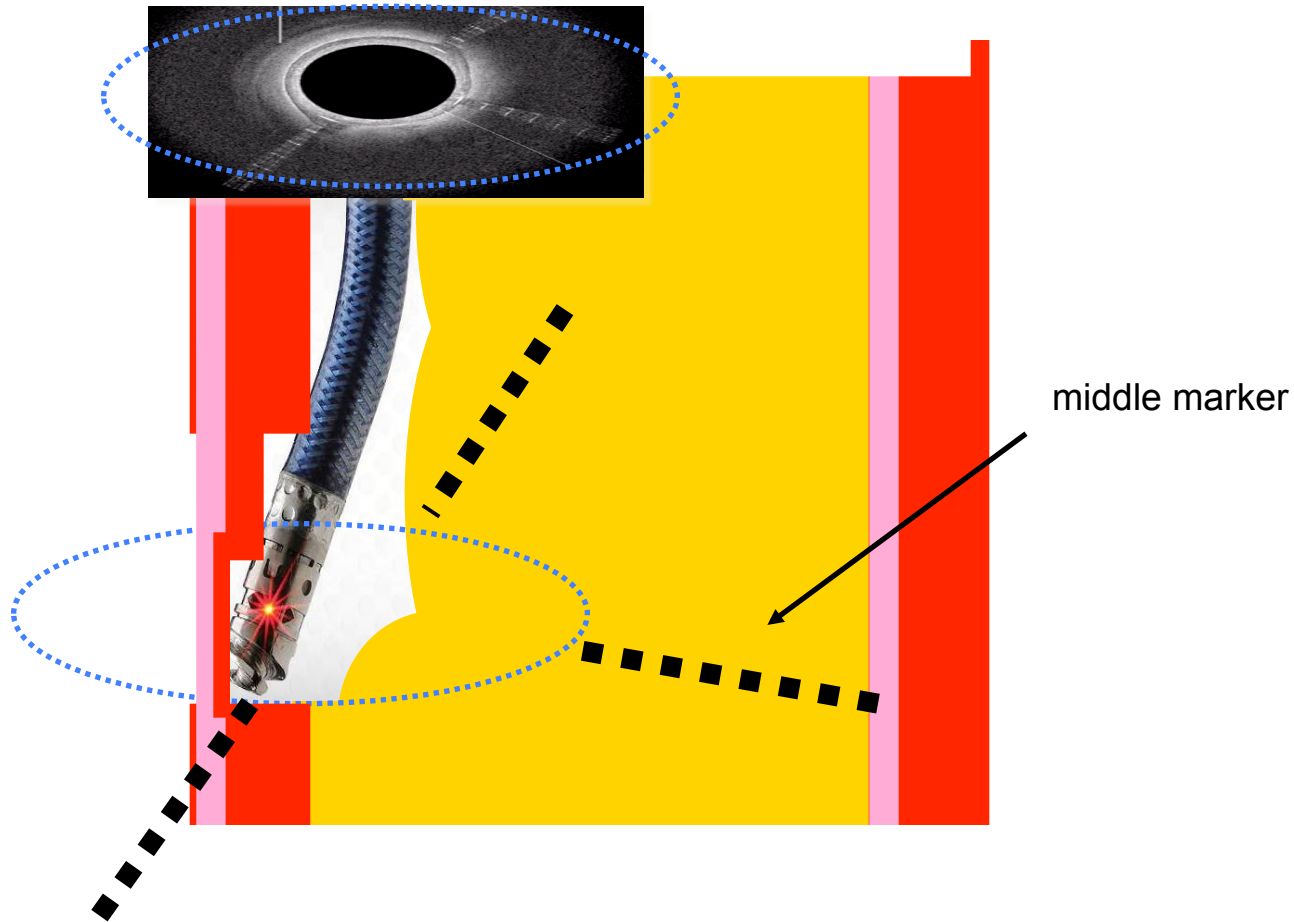
A.Schwandt



Principle of OCT-guided CTO-Recanalisation



Principle of OCT-guided CTO-Recanalisation



european market release experience Mirano/Leipzig/Münster

33 patients treated 10+12.2011

medium lesion length 22.6cm



European experience from market release study Mirano/Leipzig/Münster

Measures	Ocelot N=33
Key Safety Measures, %	100%
Freedom from clinically significant perforations, embolizations, or \geq grade C dissections	
Key Efficacy Measures, %	94%
Overall crossing success	
Secondary Efficacy Measures, (mean \pm stdev)	
Procedure time, min.	83 \pm 28
Total fluoro time, min.	28 \pm 12
Total flush, ml (for Ocelot visualization only)	49 \pm 37
Contrast dose, ml	132 \pm 75



**100% Efficacy Rate Based
on CONNECT IDE
inclusion criteria**

Grading	Characteristics
None/Mild	No or minimal radio-opacities noted prior to contrast injection
Moderate	Multiple radiio-opacities noted only prior to contrast injection
Severe	Diffuse radio-opacities noted on both sides of the aterial wall

Mild calcification

Moderate calcification

Severe calcification

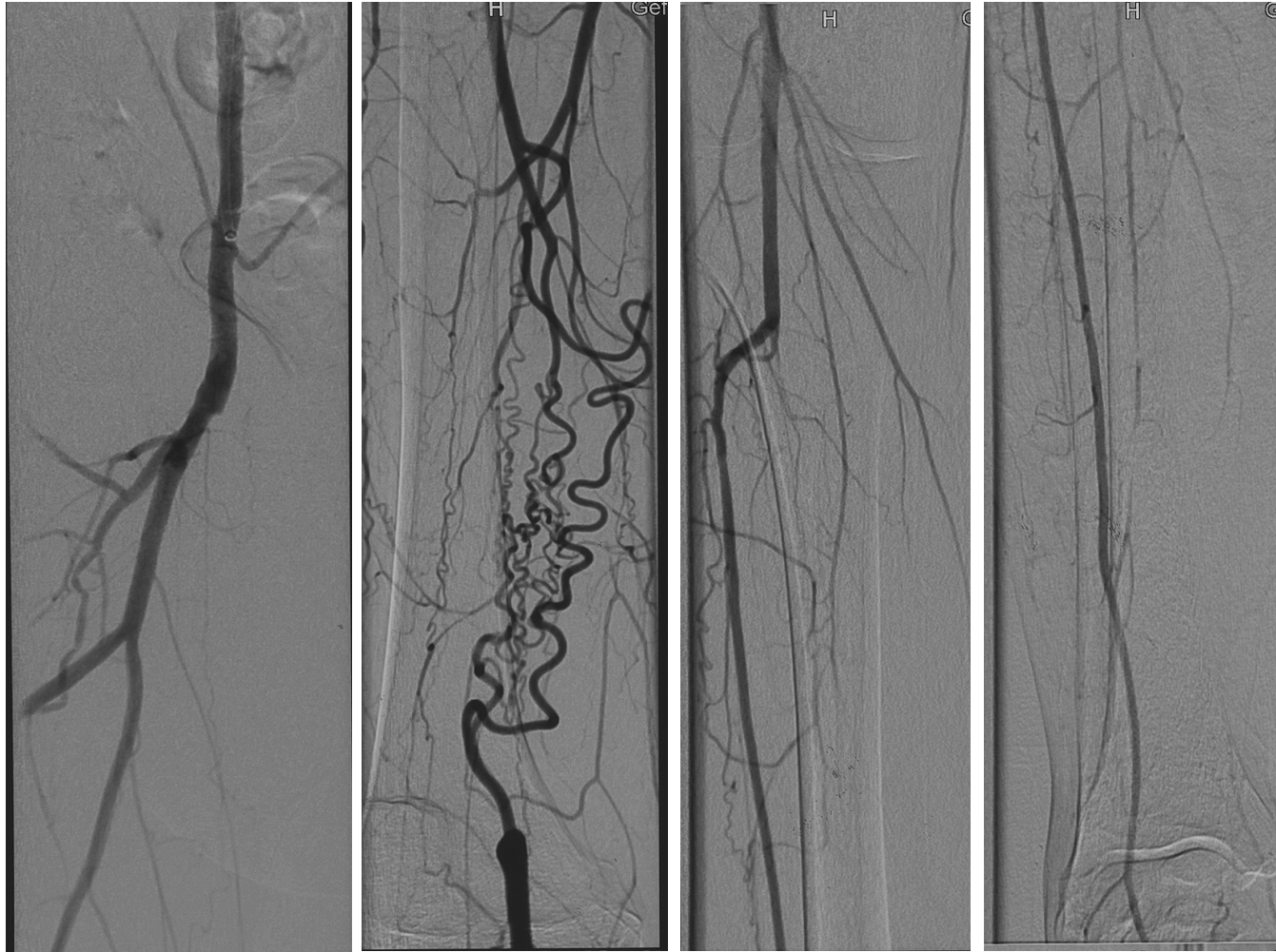
Scheinert et al 2008

Case Study 003-002

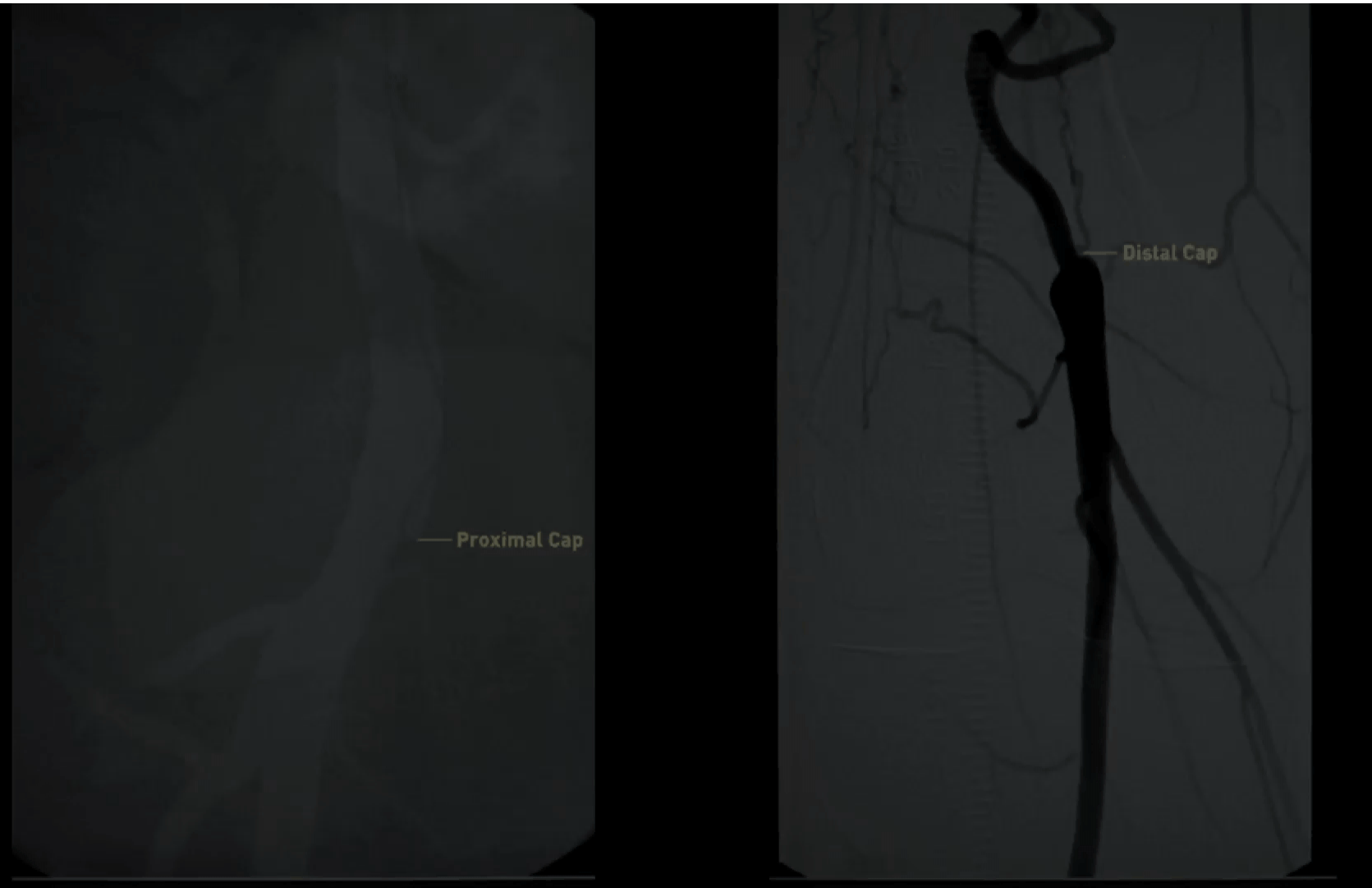
Location: St Franziskus Hospital
Muenster, Germany
Physicians: Dr. Arne Schwindt
Dr. Huey McDaniel
Lesion: 380mm

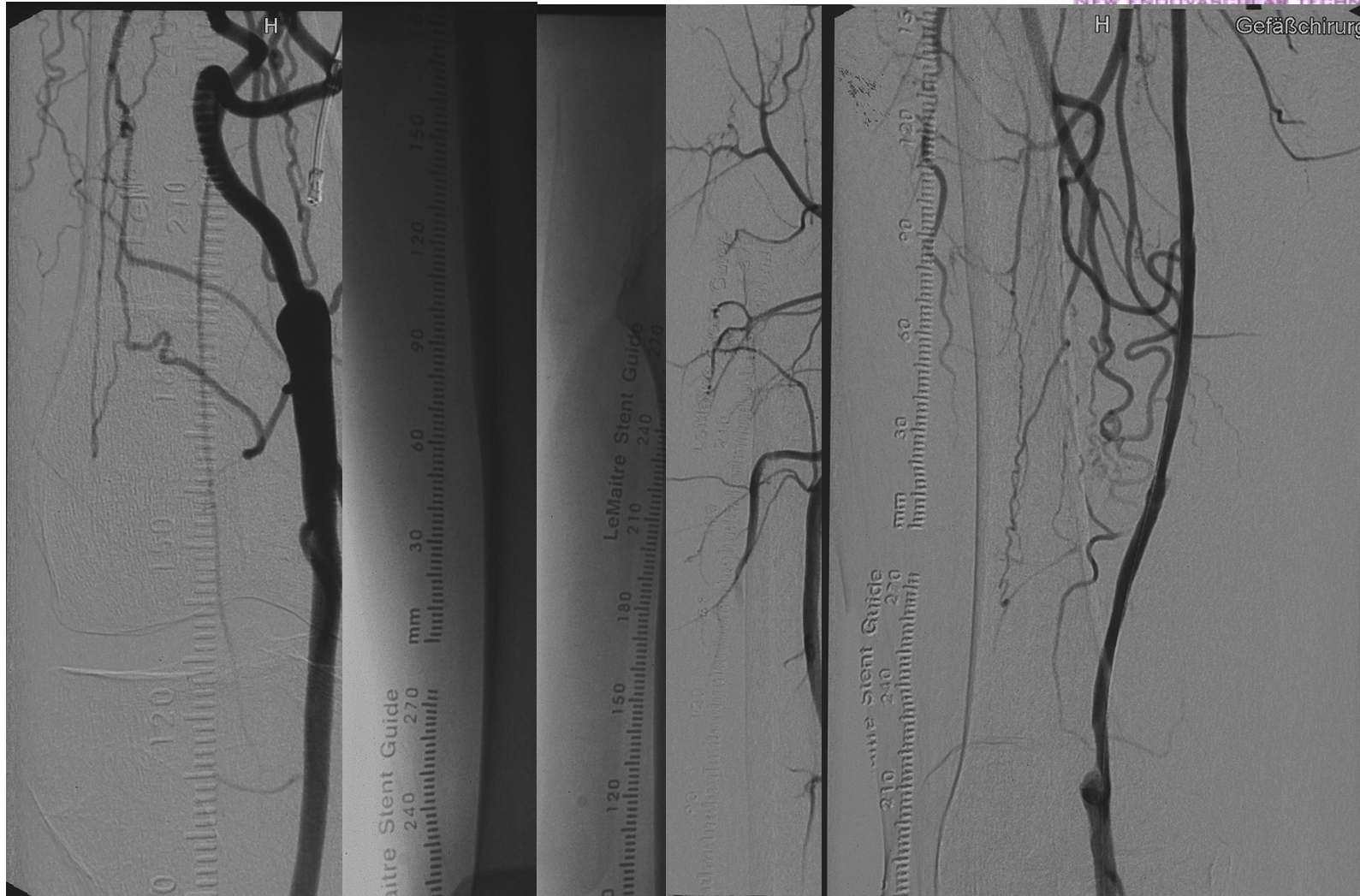


55y old male, CTO of right SFA and PI for at least 10 years
Rutherford III, wd 100m CVRF: hypertension, formerly smoker
guidewire loop attempt 2010 **and** 2008



55y old male, CTO of right SFA and PI for at least 10 years Rutherford III, wd 100m CVRF: hypertension, formerly smoker guidewire loop attempt 2010 and 2008

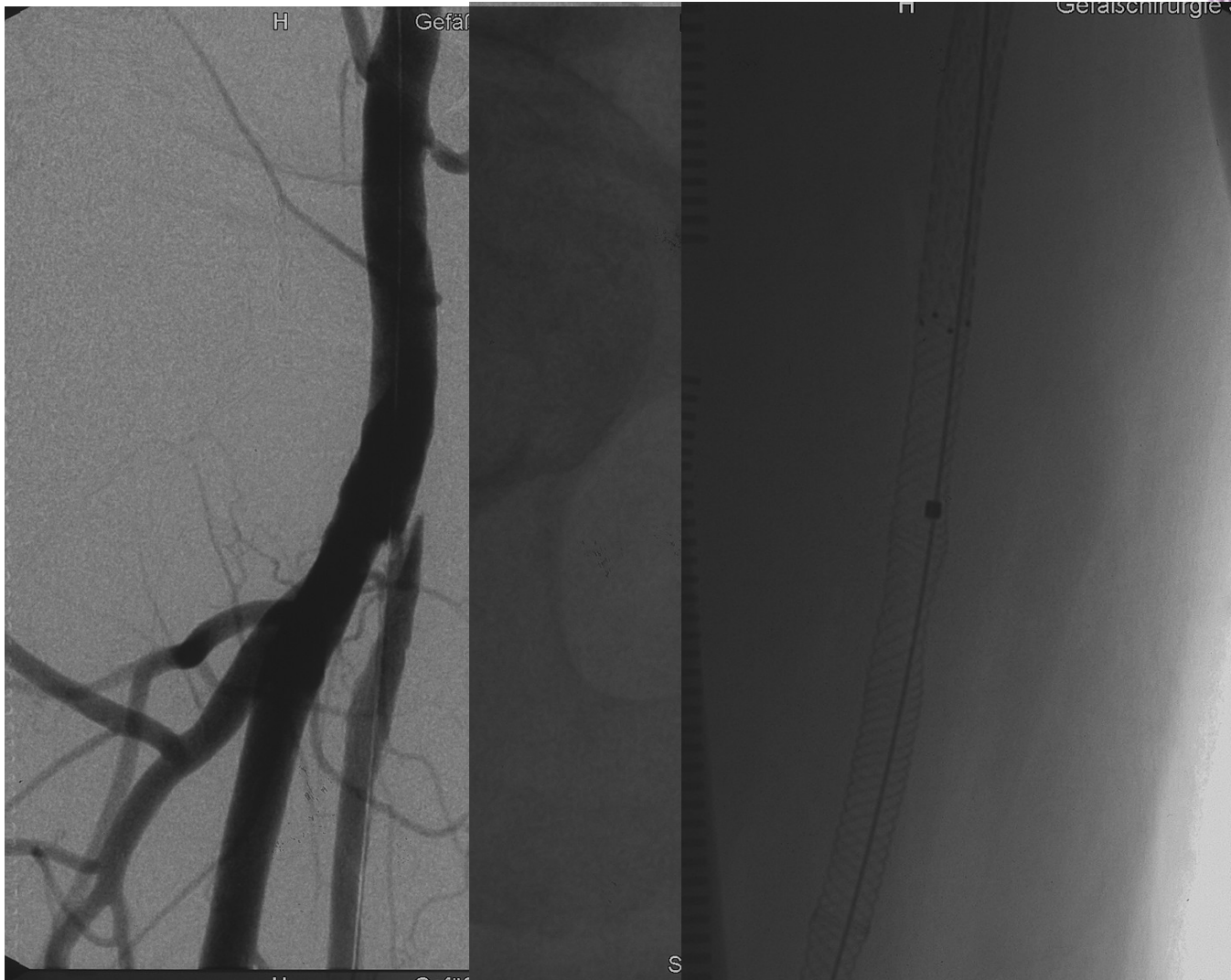




PTA 5x300 in 2 levels, Implanting 6x200 Everflex+ (Covidien) and 5x180 Supera (IDEV)

Intraluminal real-time navigation through long CTO's in the femoral artery.
Ame SCHWINDT, Münster, Germany



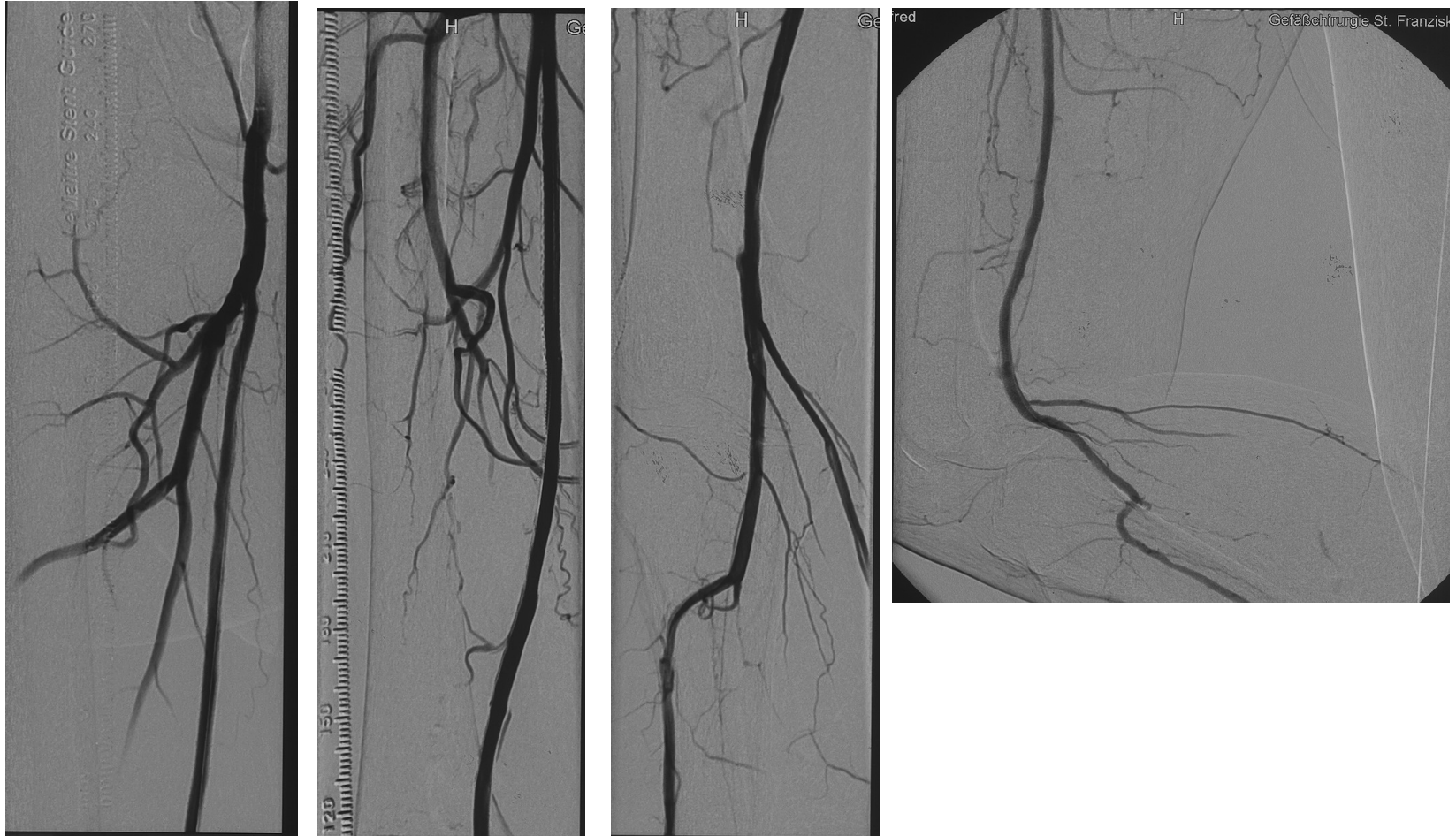


PTA 5x300 in 2 levels, Implanting 6x200 Everflex+ (Covidien) and 5x180 Supera (IDEV)

Intraluminal real-time navigation through long CTO's in the femoral artery.
Arne SCHWINDT, Münster, Germany



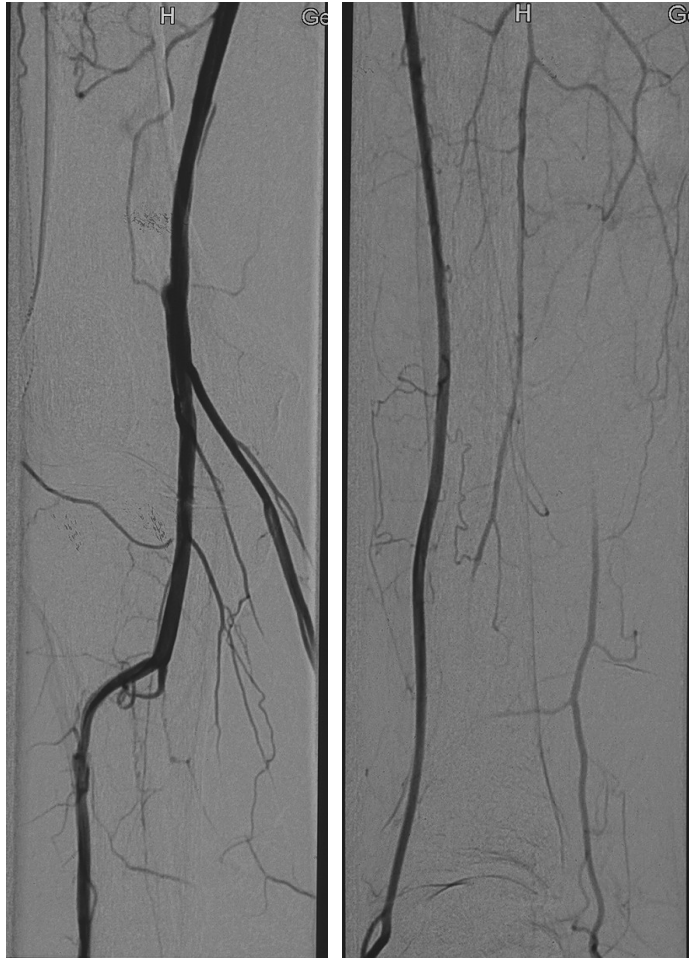Final result



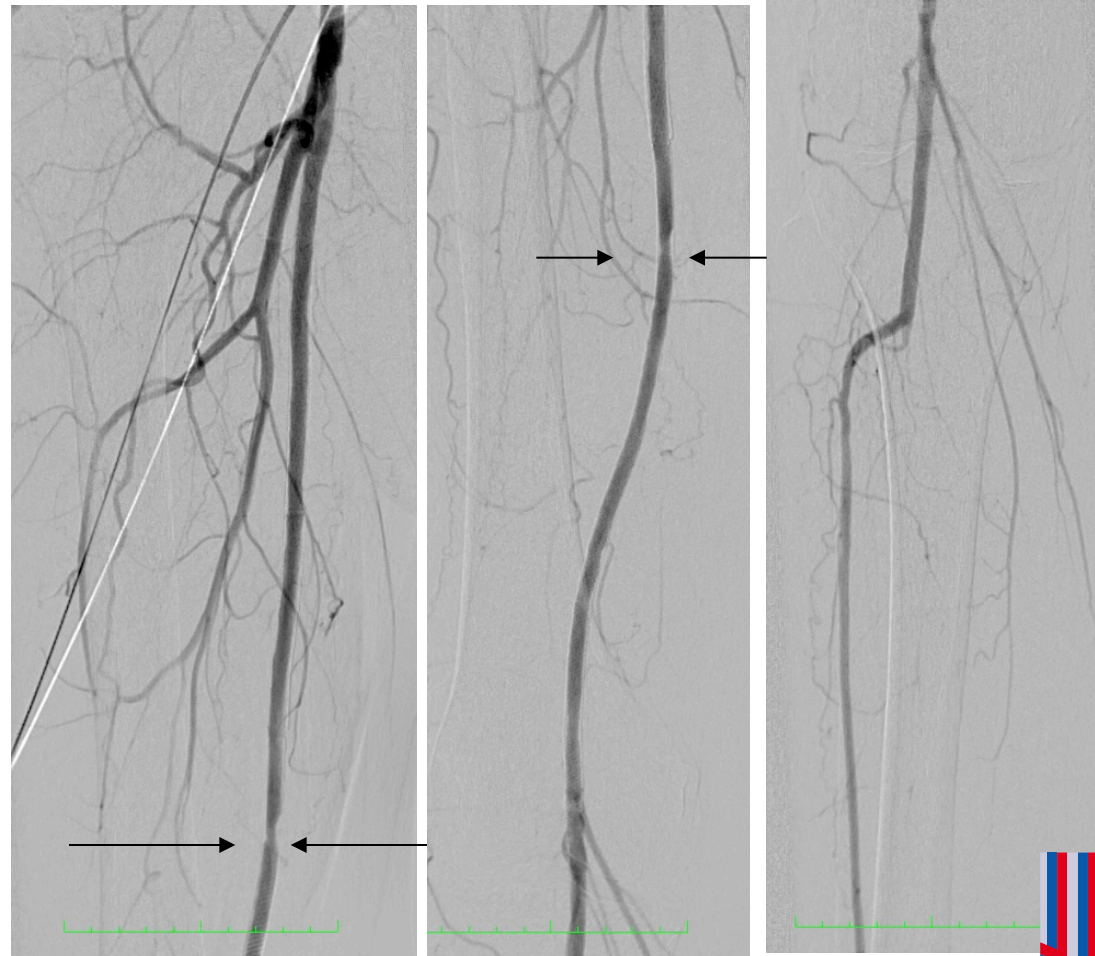
PTA 5x300 in 2 levels, Implanting 6x200 Everflex+ (Covidien) and 5x180 Supera (IDEV)



Final result



runoff after Stent-PTA



6 month fu angiography

A.Schwindt



Up-to-date results Franziskushospital Münster

A total of 124 patients with SFA CTO were treated with Ocelot100, Ocelot 150, Ocelot 200 and Ocelot PIXL (4F) catheter

A total of 5 perforations occurred, none clinical significant

Primary success rate without additional devices 85%

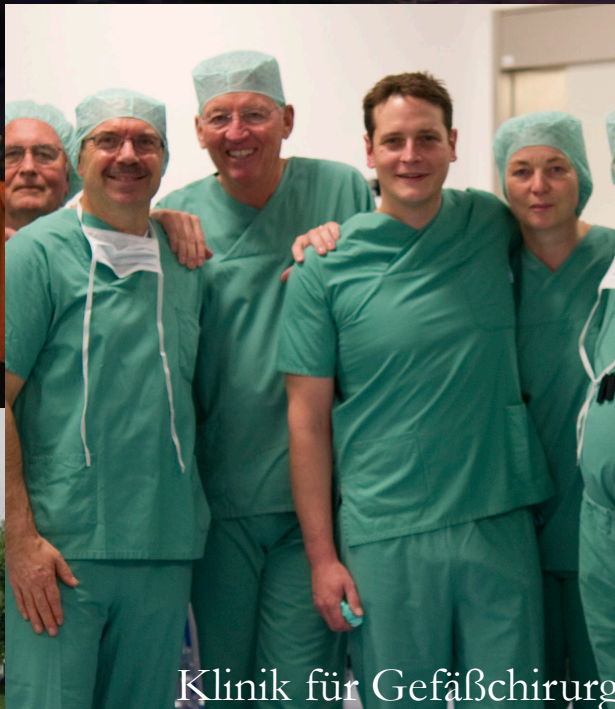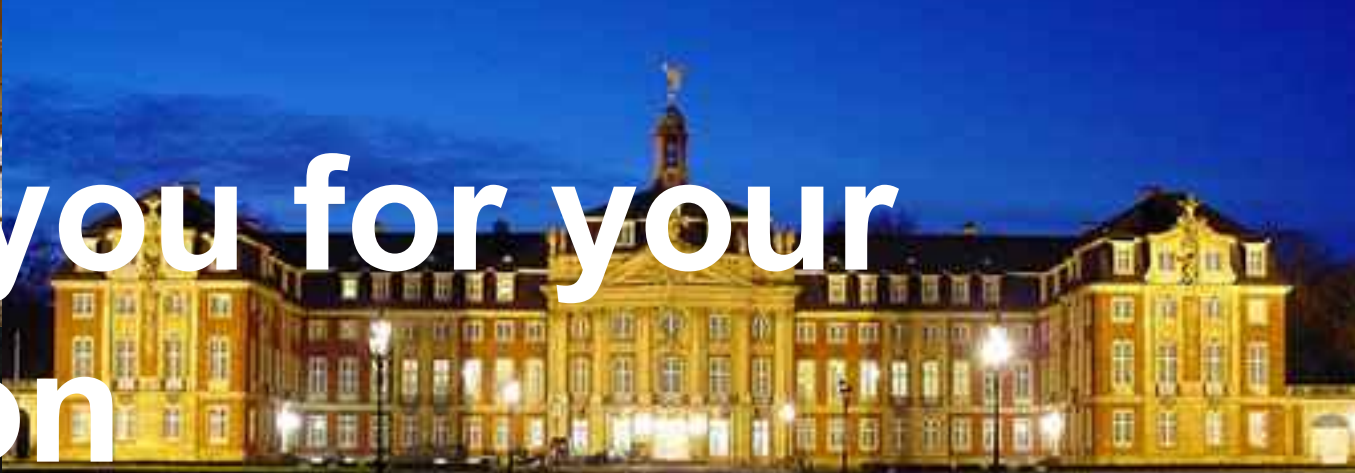Success rate with use of an additional reentry device 92%
in this real life setting

Outcomes using antiproliferative medications
(DEB/DES) should be stratified between subintimal and true
lumen crossing.





Thank you for your attention



Klinik für Gefäßchirurgie St. Franziskushospital Münster
Centrum für vaskuläre
und endovaskuläre Chirurgie Universitätsklinik Münster
<http://www.gefaesschirurgie-muenster.de/>

